



## HISTOLOGICAL ANALYSIS OF FEMORAL BONES IN RABBITS ADMINISTERED BY AMYGDALIN

*Veronika Kováčová, Radoslav Omelka, Anna Šarocká, Patrik Šranko, Mária Adamkovičová,  
Róbert Toman, Marek Halenár, Adriana Kolesárová, Monika Martiniaková*

### ABSTRACT

Cyanogenic glycosides are present in several economically important plant foods. Amygdalin, one of the most common cyanoglucoside, can be found abundantly in the seeds of apples, bitter almonds, apricots, peaches, various beans, cereals, cassava and sorghum. Amygdalin has been used for the treatment of cancer, it shows killing effects on cancer cells by release of cyanide. However, its effect on bone structure has not been investigated to date. Therefore, the objective of this study was to determine a possible effect of amygdalin application on femoral bone microstructure in adult rabbits. Four month old rabbits were randomly divided into two groups of three animals each. Rabbits from E group received amygdalin intramuscularly at a dose 0.6 mg.kg<sup>-1</sup> body weight (bw) (group E, n = 3) one time per day during 28 days. The second group of rabbits without amygdalin supplementation served as a control (group C, n = 3). After 28 days, histological structure of femoral bones in both groups of rabbits was analysed and compared. Rabbits from E group displayed different microstructure in middle part of the compact bone and near endosteal bone surface. For endosteal border, an absence of the primary vascular longitudinal bone tissue was typical. This part of the bone was formed by irregular Haversian and/or by dense Haversian bone tissues. In the middle part of *substantia compacta*, primary vascular longitudinal bone tissue was observed. Cortical bone thickness did not change between rabbits from E and C groups. However, rabbits from E group had a significantly lower values of primary osteons' vascular canals and secondary osteons as compared to the C group. On the other hand, all measured parameters of Haversian canals did not differ between rabbits from both groups. Our results demonstrate that intramuscular application of amygdalin at the dose used in our study affects femoral bone microstructure in rabbits.

**Keywords:** amygdalin; femoral bone; rabbit; histomorphometry

### INTRODUCTION

Cyanogenic glycosides are natural plant toxicants (Bolarinwa et al., 2015). All cyanogenic glycosides are potentially dangerous due to production of hydrogen cyanide (HCN) by their hydrolysis (Vetter, 2000), known as prussic acid (Francisco and Pinotti, 2000). Consumption of cyanogenic plants may cause acute and chronic toxicity in both animals and humans (Yildirim and Askin, 2010).

Amygdalin, D-mandelonitrile-β-D-gentiobioside, C<sub>20</sub>H<sub>27</sub>NO<sub>11</sub>, is one of the most frequently occurring cyanogenic glycosides (Bolarinwa et al., 2014). It is especially presented in fruit kernels of peaches, apricots, bitter almonds (Blaheta et al., 2016), pears, plums and apples (Kolesár et al., 2015). Amygdalin is composed of two molecules of glucose, one of benzaldehyde and one of hydrocyanic acid (Chang et al., 2006; Abdel-Rahman, 2011).

Amygdalin itself is non-toxic, but it is able to generate toxic hydrogen cyanide (HCN) (Bolarinwa et al., 2014) which is decomposed by some endogenous plant enzymes (Song and Xu, 2014; Kolesár et al., 2015). Amygdalin has been used as a one of the most popular alternative treatments of cancer, asthma, atherosclerosis,

hypertension, migraine and chronic inflammation (Cheng et al., 2015). However, the Food and Drug Administration (FDA) has not approved amygdalin as a therapeutic agent owing to insufficient clinical evidence of its positive efficacy and potential toxicity (Zhou et al., 2012; Halenár et al., 2015). The acute lethal dose of peroral application of HCN for human ranges between 0.5 and 3.5 mg.kg<sup>-1</sup> bw (Speijers, 1993; Bolarinwa et al., 2014). The maximum tolerance dose of intramuscular injection of amygdalin is 3 g.kg<sup>-1</sup> bw in rabbits (Song and Xu, 2014).

Amygdalin has a stimulating effect on the growth of skeletal muscle cells (line C2C12) which is dose-dependent (Yang et al., 2014). However, the impact of amygdalin on bone microstructure is still unknown. Therefore, the aim of our study was to investigate the effect of intramuscular application of amygdalin on femoral bones microstructure in adult male rabbits.

### MATERIAL AND METHODOLOGY

Adult male rabbits (n = 6) of outbred line P91 (Californian broiler line) were used in the experiment. The animals (at the age of 4 months, weighing 4 ± 0.2 kg) were obtained from an experimental farm of the Animal Production Research Centre in Nitra, Slovak Republic.

Males were housed in individual flat-deck wire cages (area 0.3 m<sup>2</sup>) under standard conditions (temperature 20 – 22 °C, humidity 55 ±10%, 12/12 h cycle of light and darkness) with access to food (feed mixture) and drinking water *ad libitum*.

Clinically healthy animals were randomly divided into two groups of three individuals each. In the experimental group (E), adult rabbits were intramuscularly injected with amygdalin (99% purity, Sigma-Aldrich, St. Louis, MO, USA) at the dose 0.6 mg.kg<sup>-1</sup> bw one time per day during 28 days. The second group (C; n = 3) without amygdalin addition served as a control. All experimental procedures were approved by the State Veterinary and Food Institute of Slovak Republic, no. 3398/11-221/3 and Ethic Committee.

After 28 days, all the rabbits were euthanized and their femurs were collected for microscopical analysis. Right femurs were sectioned at the midshaft of the diaphysis and the segments were fixed in HistoChoice fixative (Amresco, USA). The segments were then dehydrated in increasing grades (40 to 100%) of ethanol and embedded in Biodur epoxy resin (Günter von Hagens, Heidelberg, Germany) according to the method described by **Martiniaková et al., (2008)**. Transverse thin sections (70 – 80 µm) were prepared with a sawing microtome (Leitz 1600, Leica, Wetzlar, Germany) and fixed onto glass slides by Eukitt (Merck, Darmstadt, Germany) as previously described (**Martiniaková et al., 2010**). The qualitative histological characteristics of the compact bone tissue were determined according to the internationally accepted classification systems of **Enlow and Brown (1956)** and **Ricqlés et al. (1991)**. The quantitative (histomorphometrical) variables were assessed using the software Motic Images Plus 2.0 ML (Motic China Group Co., Ltd.). We measured area, perimeter and the minimum and maximum diameters of primary osteons' vascular canals, Haversian canals and secondary osteons in all views (i.e., anterior, posterior, medial and lateral) of the thin sections in order to minimize inter-animal differences. Diaphyseal cortical bone thickness was also measured by Motic Images Plus 2.0 ML software. Twenty random areas were selected, and average thickness was calculated for each femur.

Statistical analysis was performed using SPSS 8.0 software. All data were expressed as mean ±standard deviation (SD). The unpaired Student's T-test was used for establishing statistical significance ( $p < 0.05$ ) between both groups of rabbits.

## RESULTS AND DISCUSSION

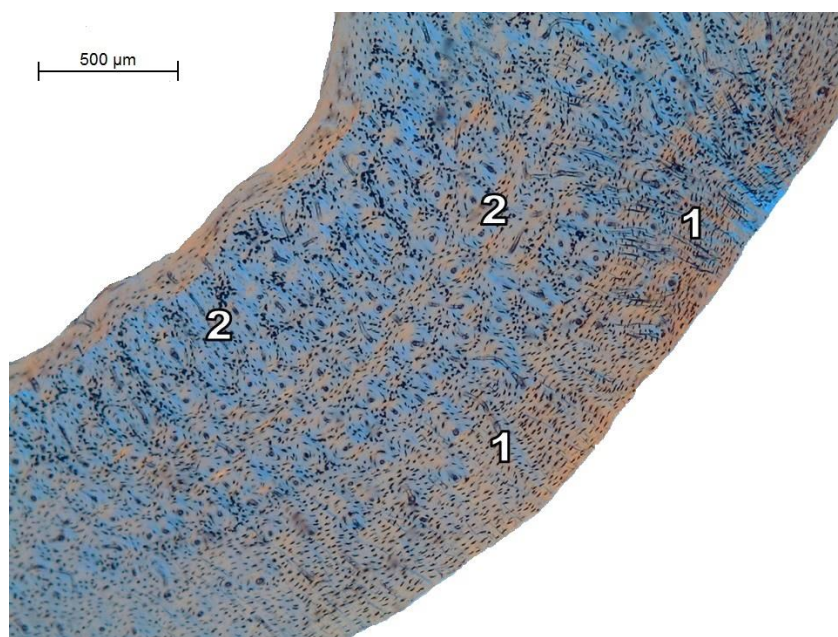
Femoral diaphysis of rabbits from the C group had the following microstructure in common. Primary vascular longitudinal bone tissue, as a basic structural pattern of rabbit's bones, formed the endosteal and periosteal borders. This tissue contained vascular canals which ran in a direction essentially parallel to the long axis of the bone. Near endosteal and periosteal borders, primary vascular radial bone tissue occurred (mainly in anterolateral and anteromedial views). It was created by branching or non-branching vascular canals radiating from the marrow cavity or *periosteum*. The middle part of the compact bone was composed by dense Haversian bone tissue with a high concentration of secondary osteons. Several secondary

osteons were also observed near the endosteal surface (especially in the anterior and posterior views) (Figure 1).

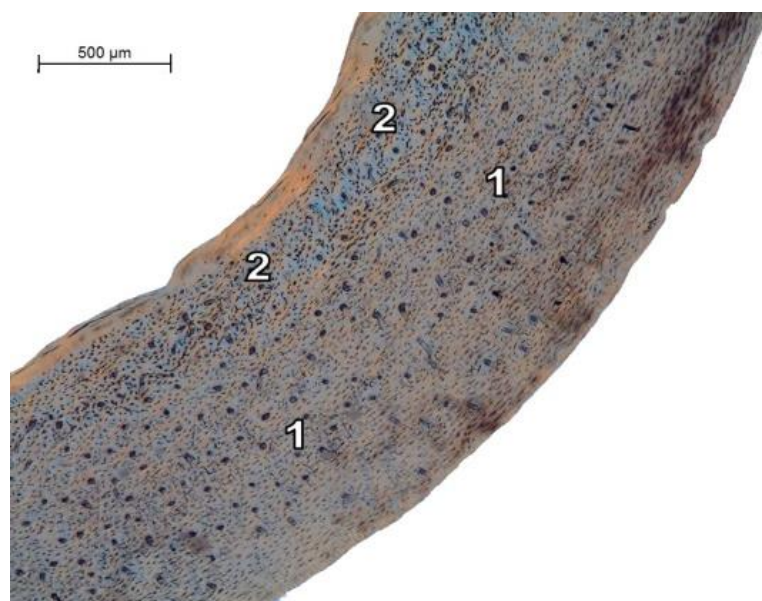
Rabbits intramuscularly administered by amygdalin (E group) had different bone microstructure in the middle part of the *substantia compacta* and near endosteal bone surface. For endosteal border, an absence of the primary vascular longitudinal bone tissue was typical (mainly in anterolateral and anteromedial views). Endosteal surface was formed by irregular Haversian tissue (characterized by occurrence of scattered secondary osteons) and/or by dense Haversian bone tissue. In the middle part of *substantia compacta*, primary vascular longitudinal bone tissue was observed (it extended there from *periosteum*). Also, no secondary osteons were presented there. The periosteal surface was composed of primary vascular longitudinal bone tissue (Figure 2).

The results of qualitative histological analysis in rabbits from the C group corresponded with previous studies (**Enlow and Brown, 1956; Martiniaková et al., 2003; Martiniaková et al., 2009**). However, intramuscular application of amygdalin (in rabbits from E group) induced changes near endosteal bone surface and also in the middle part of the compact bone. Central area of the compact bone was composed of primary vascular longitudinal bone tissue. Secondary osteons were found only near endosteal border. This phenomenon can be associated with adaptation of bone tissue to amygdalin exposure. This mechanism might prevent towards bone cells apoptosis and bone tissue necrosis. The experiment by **Shou et al., (2000)** has shown that cyanide treatment induced apoptosis by inducing oxidative stress in cortical neurons. It is known that bone is richly innervated (**Marenzana and Chenu, 2008**). Nerve endings are in direct contact with bone cells (**He et al., 2013**), indicating that nerve fibers may regulate growth and remodeling of the bone. It was found that sympathetic denervation induced abnormal formation and resorption of bone (**Chenu and Marenzana, 2005**). Also, increased bone resorption was observed in rats after removal of sympathetic nerve supply (**He et al., 2011**).

Therefore, the absence of primary vascular longitudinal bone tissue near endosteal surface in rabbits from E group can be connected with intensive endosteal resorption due to amygdalin administration. Generally, skeletal system is a dynamic organ and is constantly undergoing remodeling, which is enabled by osteoblasts and osteoclasts (**Guntur and Rosen, 2012; Arakaki et al., 2013**). The formation and activation of osteoclasts to enhance bone resorption have shown to be associated with the higher generation of oxygen-derived free radicals (**Garrett et al., 1990; Baek et al., 2010**). **Gunasekar et al., (1998)** reported that excessive production of reactive oxygen species (ROS) might be cyanide-induced. With accordance with this finding, **Daya et al., (2000)** reported that cyanide led to generation of oxidative stress and also lipid peroxidation which are associated with hypoxia (**Gunasekar et al., 1998**). **Chang et al., (2014)** found that hypoxia reduced proliferative activity of osteoblasts and inhibited mineralization and bone formation. On the other hand, hypoxia increased formation of osteoclasts (**Patntirapong and Hauschka, 2007; Arnett, 2010**) and activity of these cells (**Knowles and Athanasou, 2009**). The authors (**Patntirapong and Hauschka, 2007**) further stated that



**Figure 1** Microscopical structure of femoral bone in rabbits from the C group:  
1 – primary vascular longitudinal bone tissue,  
2 – dense Haversian bone tissue.



**Figure 2** Microscopical structure of femoral bone in rabbits from the E group:  
1 – primary vascular longitudinal bone tissue,  
2 – dense Haversian bone tissue.

low concentration of oxygen may change homeostasis of bone, leading to osteolysis, osteonecrosis (Martiniaková et al., 2013b) and osteoporosis (Alagiakrishnan et al., 2003). Our results also showed increased periosteal bone apposition due to amygdalin administration which can serve as a compensatory mechanism to enormous endosteal bone reduction (Szulc et al., 2006).

Our results showed an – non-significant effect of amygdalin application on cortical bone thickness in male rabbits (1085.15 ±145.54 mm and 1053.90 ±153.17 mm in rabbits from E and C groups, respectively).

For the quantitative histological analysis, 196 vascular canals of primary osteons, 98 Haversian canals and 98 secondary osteons were measured in both groups of

rabbits. The results are summarized in Tables 1, 2 and 3. We have found that intramuscular application of amygdalin significantly affected sizes of the primary osteons' vascular canals and secondary osteons. Primary osteons' vascular canals and secondary osteons were significantly lower ( $p < 0.05$ ) in males from the E group. On the other hand, the size of Haversian canals did not differ between rabbits from both groups.

Rabbits injected with amygdalin had significantly lower values of primary osteons' vascular canals. This finding could be connected with a negative impact of amygdalin on blood vessels which are situated in vascular canals of primary osteons (Currey, 2002; Greenlee and Dunnell, 2010).

**Table 1** Data on primary osteons' vascular canals in rabbits from E and C groups.

Rabbit's group	N	Area ( $\mu\text{m}^2$ )	Perimeter ( $\mu\text{m}$ )	Max. diameter ( $\mu\text{m}$ )	Min. diameter ( $\mu\text{m}$ )
E	96	290.67 $\pm$ 48.08	61.40 $\pm$ 5.40	10.76 $\pm$ 1.31	8.66 $\pm$ 0.99
C	100	314.33 $\pm$ 63.56	63.73 $\pm$ 6.67	11.14 $\pm$ 1.51	9.01 $\pm$ 1.18
T-test		$p < 0.05$	$p < 0.05$	NS	NS

Note: N: number of measured structures; NS: non-significant changes.

**Table 2** Data on Haversian canals in rabbits from E and C groups.

Rabbit's group	N	Area ( $\mu\text{m}^2$ )	Perimeter ( $\mu\text{m}$ )	Max. diameter ( $\mu\text{m}$ )	Min. diameter ( $\mu\text{m}$ )
E	49	338.25 $\pm$ 73.78	66.05 $\pm$ 6.83	11.64 $\pm$ 1.30	9.23 $\pm$ 1.29
C	49	343.88 $\pm$ 58.93	67.18 $\pm$ 5.63	11.93 $\pm$ 1.40	9.24 $\pm$ 1.22
T-test		NS	NS	NS	NS

Note: N: number of measured structures; NS: non-significant changes.

**Table 3** Data on secondary osteons in rabbits from E and C groups.

Rabbit's group	N	Area ( $\mu\text{m}^2$ )	Perimeter ( $\mu\text{m}$ )	Max. diameter ( $\mu\text{m}$ )	Min. diameter ( $\mu\text{m}$ )
E	49	4887.19 $\pm$ 2408.89	245.70 $\pm$ 62.40	43.42 $\pm$ 11.55	33.95 $\pm$ 9.16
C	49	6849.68 $\pm$ 2795.79	291.70 $\pm$ 57.75	50.66 $\pm$ 9.85	41.54 $\pm$ 9.50
T-test		$p < 0.05$	$p < 0.05$	$p < 0.05$	$p < 0.05$

Note: N: number of measured structures.

Waypa et al., (2001) reported that cyanide caused vasoconstriction. According to Hamel (2011) hypoxia has a negative effect on cardiovascular system and induced constriction of pulmonary arteries and dilatation in systemic arteries (Weir and Archer, 1995). Higher levels of ROS production are associated with endothelial dysfunction like atherosclerosis and hypertension (Guzik et al., 2011). Cheng et al., (2015) found that amygdalin increased the intracellular calcium level which can be associated with atherosclerosis (Henry, 1985; Orimo and Ouchi, 1990). According to many authors (Baum and Moe, 2008; Yarema and Yost, 2011) glucocorticoid hormones have essential roles in homeostatic regulation and stress adaptation. These types of hormones cause vasoconstriction of blood vessels and mediate hypertension (Saruta, 1996; Ponticelli and Glassock, 2009). According to Ullian (1999) application of hydrocortisone or corticosterone into rabbit aortic strips leads to greatly potentiated contractile responses to norepinephrine. Also Berecek and Bohr (1978) mentioned that deoxycorticosterone application stimulated vasoconstrictive effect of norepinephrine and angiotensin II in pigs. Based on these findings, we assume that the significant reduction of the size of primary osteons' vascular canals could be associated with these aspects.

On the other hand, non-significant changes in the size of Haversian canals were observed in rabbits from E group. It is generally known that the structure of primary and secondary osteons is different. Secondary osteons and also Haversian canals are surrounded by a cement line which is not found in primary osteons (Currey, 2002; Martiniaková et al., 2013b). We suppose that the cement line is a main reason for different results in histomorphometry of both canals.

We have also found significantly lower secondary osteons in rabbits from E group. It is known that collagen type I

(the major organic component of mineralized bone matrix, Buchwald et al., 2012) is produced by osteoblasts (Bosetti et al., 2003; Wang et al., 2012). Secondary osteons are formed by lamellae in which collagen fibers run parallel to each other (Martiniaková et al., 2013b). The arrangement of collagen fibers in lamellae of secondary osteons ensures strength (Dylevský, 2009) and biochemical properties of the compact bone (Martiniaková et al., 2013a). According to Wang et al., (2012) osteoblasts also synthesize alkaline phosphatase (ALP) which promotes mineralization of bone matrix. Mody et al., (2001) observed increase of intracellular oxidative stress and inhibition of differentiation markers in osteoblasts. The same findings have also been documented in the study of Bai et al., (2004). In addition, these authors observed a reduction in the expression of collagen type I and ALP in rabbits calvarial osteoblasts. The experiment by Arai et al., (2007) has shown that bone mineralization significantly decreased by hydrogen peroxide (the most important ROS) exposure. Therefore, changes in the size of secondary osteon's may be associated with the inhibitory effect of oxidative stress (caused by amygdalin) on the osteoblastic activity which is connected with a reduction of collagen (Patntirapong and Hauschka, 2007).

## CONCLUSION

Natural plant substances like amygdalin are still a major part of traditional medicine. However, its effect on animal and human organisms is still not clear. Our results demonstrate that administration of amygdalin at the dose 0.6 mg.kg<sup>-1</sup> bw one time per day during 28 days induced changes in femoral bone microstructure of rabbits. Primary vascular longitudinal bone tissue was not found near endosteal surface. On the other hand, it was observed near *periosteum* and also in the middle part of *substantia*

*compacta*. Moreover, an absence of secondary osteons in the central area of the bone was identified in amygdalin-injected rabbits. Also, rabbits from E group had significantly lower ( $p < 0.05$ ) values of primary osteons' vascular canals and secondary osteons as compared to the C group.

## REFERENCES

- Abdel-Rahman, M. K. 2011. Can apricot kernels fatty acids delay the atrophied hepatocytes from progression to fibrosis in dimethylnitrosamine (DMN)-induced liver injury in rats? *Lipids in Health and Disease*, vol. 10, no. 114, p. 1-10. <http://dx.doi.org/10.1186/1476-511X-10-114>
- Alagiakrishnan, K., Juby, A., Hanley, D., Tymchak, W., Sclater, A. 2003. Role of Vascular Factors in Osteoporosis. *The Journal of Gerontology. Series A, Biological Sciences and Medical Sciences*, vol. 58, no. 4, p. 362-366. <http://dx.doi.org/10.1093/gerona/58.4.M362>  
PMid: 12663699
- Arai, M., Shibata, Y., Pugdee, K., Abiko, Y., Ogata, Y. 2007. Effects of reactive oxygen species (ROS) on antioxidant system and osteoblastic differentiation in MC3T3-E1 cells. *UIBMB Life*, vol. 59, no. 1, p. 27-33. [doi:10.1080/15216540601156188](http://dx.doi.org/10.1080/15216540601156188)  
PMid: 17365177
- Arakaki, N., Yamashita, A., Niimi, S., Yamazaki, T. 2013. Involvement of reactive oxygen species in osteoblastic differentiation of MC3T3-E1 cells accompanied by mitochondrial morphological dynamics. *Biomedical Research*, vol. 34, no. 3, p. 161-166. <http://dx.doi.org/10.2220/biomedres.34.161>  
PMid: 23782750
- Arnett, T. R. 2010. Acidosis, hypoxia and bone. *Archives of Biochemistry and Biophysics*, vol. 503, no. 1, p. 103-109. <http://dx.doi.org/10.1016/j.abb.2010.07.021>
- Baek, K. H., Oh, K. W., Lee W. Y., Lee, S. S., Kim, M. K., Kwon, H. S., Rhee, E. J., Han, J. H., Song, K. H., Cha, B. Y., Lee, K. W., Kang, M. I. 2010. Association of Oxidative Stress with Postmenopausal Osteoporosis and the Effects of Hydrogen Peroxide on Osteoclast Formation in Human Bone Marrow Cell Culture. *Calcified Tissue International*, vol. 87, no. 3, p. 226-235. <http://dx.doi.org/10.1007/s00223-010-9393-9>  
PMid: 20614110
- Bai, X., Lu, D., Bai, J., Zheng, H., Ke, Z., Li, X., Luo, S. 2004. Oxidative stress inhibits osteoblastic differentiation of bone cells by ERK and NF- $\kappa$ B. *Biochemical and Biophysical Research Communications*, vol. 314, no. 1, p. 197-207. <http://dx.doi.org/10.1016/j.bbrc.2003.12.073>  
PMid: 14715266
- Baum, M., Moe, O. W. 2008. Glucocorticoid-Mediated Hypertension: Does the Vascular Smooth Muscle Hold All the Answers? *Journal of the American Society of Nephrology*, vol. 19, no. 7, p. 1251-1253. <http://dx.doi.org/10.1681/ASN.2008040410>  
PMid: 18508960
- Berecek, K. H., Bohr, D. F. 1978. Whole Body Vascular Reactivity during the Development of Deoxycorticosterone Acetate Hypertension in the Pig. *Circulation Research*, vol. 42, no. 6, p. 764-771. <http://dx.doi.org/10.1161/01.RES.42.6.764>  
PMid: 657435
- Blaheta, R. A., Nelson, K., Haferkamp, A., Juengel, E. 2016. Amygdalin, quackery or cure? *Phytomedicine*, vol. 23, no. 4, p. 367-376. <http://dx.doi.org/10.1016/j.phymed.2016.02.004>
- Bolarinwa, I. F., Orfila, C., Morgan, M. R. A. 2014. Amygdalin content of seeds, kernels and food products commercially-available in the UK. *Food Chemistry*, vol. 152, p. 133-139. <http://dx.doi.org/10.1016/j.foodchem.2013.11.002>  
PMid: 24444917
- Bolarinwa, I. F., Orfila, C., Morgan, M. R. A. 2015. Determination of amygdalin in apple seeds, fresh apples and processed apple juices. *Food Chemistry*, vol. 170, p. 437-442. <http://dx.doi.org/10.1016/j.foodchem.2014.08.083>  
PMid: 25306368
- Bosetti, M., Zanardi, L., Hench, L., Cannas, M. 2003. Type I collagen production by osteoblast-like cells cultured in contact with different bioactive glasses. *Journal of Biomedical Materials Research part A*, vol. 64, no. 1, p. 189-195. <http://dx.doi.org/10.1002/jbm.a.10415>  
PMid: 12483713
- Buchwald, T., Kozielski, M., Szybowicz, M. 2012. Determination of Collagen Fibers Arrangement in Bone Tissue by Using Transformations of Raman Spectra Maps. *Spectroscopy: An International Journal*, vol. 27, no. 2, p. 107-117. <http://dx.doi.org/10.1155/2012/261487>
- Chang, H. K., Shin, M. S., Yang, H. Y., Lee, J. W., Kim, Y. S., Lee, M. H., Kim, J., Kim, K. H., Kim, C. J. 2006. Amygdalin Induces Apoptosis through Regulation of Bax and Bcl-2 Expressions in Human DU145 and LNCaP Prostate Cancer Cells. *Biological and Pharmaceutical Bulletin*, vol. 29, no. 8, p. 1597-1602. <http://dx.doi.org/10.1248/bpb.29.1597>  
PMid: 16880611
- Chang, J., Jackson, S. G., Wardale, J., Jones, S. W. 2014. Hypoxia Modulates the Phenotype of Osteoblasts Isolated From Knee Osteoarthritis Patients, Leading to Undermineralized Bone Nodule Formation. *Arthritis and Rheumatology*, vol. 66, no. 7, p. 1789-1799. <http://dx.doi.org/10.1002/art.38403>  
PMid: 24574272
- Cheng Y., Yang, C., Zhao, J., Tse, H. F., Ring, J. 2015. Proteomic identification of calcium-binding chaperone calreticulin as a potential mediator for the neuroprotective and neuritogenic activities of fruit-derived glycoside amygdalin. *The Journal of Nutritional Biochemistry*, vol. 26, no. 2, p. 146-154. <http://dx.doi.org/10.1016/j.jnutbio.2014.09.012>  
PMid: 25465157
- Chenu, C., Marenzana, M. 2005. Sympathetic nervous system and bone remodeling. *Joint Bone Spine*, vol. 72, no. 6, p. 481-483. <http://dx.doi.org/10.1016/j.jbspin.2005.10.007>
- Currey, J. D. 2002. *Bones - Structure and Mechanics* United States: Princeton University Press, p. 436. ISBN 9780691128047.
- Daya, S., Walker, R. B., Anoopkumar-Dukie, S. 2000. Cyanide-Induced Free Radical Production and Lipid Peroxidation in Rat Homogenate is Reduced by Aspirin. *Metabolic Brain Disease*, vol. 15, no. 3, p. 203-210. <http://dx.doi.org/10.1023/A:1011163725740>  
PMid: 11206589
- Dylevský, I. 2009. Funkční anatomie. *The Functional Anatomy*. Praha: Grada Publishing, a. s., p. 544. ISBN 978-80-247-3240-4.
- Enlow, D. H., Brown, S. O. 1956. A comparative histological study of fossil and recent bone tissues. Part I. *Texas Journal of Science*, vol. 8, p. 405-412.
- Francisco, I. A., Pinotti, M. H. P. 2000. Cyanogenic Glycosides in Plants. *Brazilian Archives of Biology and Technology*, vol. 43, no. 5, p. 487-492. <http://dx.doi.org/10.1590/S1516-89132000000500007>

- Garrett, I. R., Boyce, B. F., Oreffo, R. O. C., Bonewald, L., Poser, J., Mundy, G. R. 1990. Oxygen-derived Free Radicals Stimulate Osteoclastic Bone Resorption in Rodent Bone In Vitro and In Vivo. *The Journal of Clinical Investigation*, vol. 85, no. 3, p. 632-639. <http://dx.doi.org/10.1172/JCI114485> PMID: 2312718
- Greenlee, D. M., Dunnell, R. C. 2010. Identification of fragmentary bone from the Pacific. *Journal of Archaeological Science*, vol. 37, no. 5, p. 957-970. <http://dx.doi.org/10.1016/j.jas.2009.11.029>
- Gunasekar, P. G., Borowitz, J. L., Isom, G. E. 1998. Cyanide-Induced Generation of Oxidative Species: Involvement of Nitric Oxide Synthase and Cyclooxygenase-2. *Journal of Pharmacological and Experimental Therapeutics*, vol. 285, no. 1, p. 236-241. PMID: 9536016
- Guntur, A. R., Rosen, C. J. 2012. Bone as an endocrine organ. *Endocrine Practice*, vol. 18, no. 5, p. 758-762. <http://dx.doi.org/10.4158/EP12141.RA> PMID: 22784851
- Guzik, B., Chwala, M., Matusik, P., Ludew, D., Skiba, D., Wilk, G., Mrowiecki, W., Batko, B., Cencora, A., Kapelak, B., Sadowski, J., Korbut, R., Guzik, T. J. 2011. Mechanisms of increased vascular superoxide production in human varicose veins. *Polskie Archiwum Medycyny Wewnetrznej*, vol. 121, no. 9, p. 279-286. PMID: 21860369
- Halenár, M., Medveďová, M., Maruniaková, N., Kolesárová, A. 2015. Ovarian hormone production affected by amygdalin addition *in vitro*. *Journal of Microbiology, Biotechnology and Food Sciences*, vol. 4, p. 19-22. <http://dx.doi.org/10.15414/jmbfs.2015.4.special2.19-22>
- Hamel, J. 2011. A Review of Acute Cyanide Poisoning. *Critical Care Nurse*, vol. 31, no. 1, p. 72-81. <http://dx.doi.org/10.4037/ccn2011799>
- He, J. Y., Jiang, L. S., Dai, L. Y. 2011. The roles of the sympathetic nervous system in osteoporotic diseases: A review of experimental and clinical studies. *Ageing Research Reviews*, vol. 10, no. 2, p. 253-263. <http://dx.doi.org/10.1016/j.arr.2011.01.002> PMID: 21262391
- He, J. Y., Zheng, X. F., Jiang, S. D., Chen, X. D., Jiang, L. S. 2013. Sympathetic neuron can promote osteoblast differentiation through BMP signaling pathway. *Cellular Signalling*, vol. 25, no. 6, p. 1372-1378. <http://dx.doi.org/10.1016/j.cellsig.2013.02.016> PMID: 23454096
- Henry, P. D. 1985. Atherosclerosis, calcium, and calcium antagonists. *Circulation*, vol. 72, no. 3, p. 456-459. <http://dx.doi.org/10.1161/01.CIR.72.3.456> PMID: 3893790
- Knowles, H. J., Athanasou, N. A. 2009. Acute hypoxia and osteoclast activity: a balance between enhanced resorption and increased apoptosis. *Journal of Pathology*, vol. 218, p. 256-264. <http://dx.doi.org/10.1002/path.2534> PMID: 19291710
- Kolesár, E., Halenár, M., Kolesárová, A., Massányi, P. 2015. Natural plant toxicant - cyanogenic glycoside amygdalin: characteristic, metabolism and the effect on animal reproduction. *Journal of Microbiology, Biotechnology and Food Sciences*, vol. 4, p. 49-50. <http://dx.doi.org/10.15414/jmbfs.2015.4.special2.49-50>
- Marenzana, M., Chenu, C. 2008. Sympathetic nervous system and bone adaptive response to its mechanical environment. *Journal of Musculoskeletal and Neuronal Interactions*, vol. 8, no. 2, p. 111-120. PMID: 18622080
- Martiniaková, M., Vondráková, M., Fabiš, M. 2003. Investigation of the microscopic structure of rabbit compact bone tissue. *Scripta medica (Brno)*, vol. 76, no. 4, p. 215-220.
- Martiniaková, M., Omelka, R., Grosskopf, B., Sirotkin, A. V., Chrenek, P. 2008. Sex-related variation in compact bone microstructure of the femoral diaphysis in juvenile rabbits. *Acta Veterinaria Scandinavica*, vol. 50, p. 15. <http://dx.doi.org/10.1186/1751-0147-50-15> PMID: 18522730
- Martiniaková, M., Omelka, R., Grosskopf, B., Chovancová, H., Massányi, P., Chrenek, P. 2009. Effects of dietary supplementation of nickel and nickel-zinc on femoral bone structure in rabbits. *Acta Veterinaria Scandinavica*, vol. 50, p. 15. <http://dx.doi.org/10.1186/1751-0147-51-52> PMID: 20003522
- Martiniaková, M., Omelka, R., Jančová, A., Stawarz, R., Formicki, G. 2010. Heavy metal content in the femora of yellow-necked mouse (*Apodemus flavicollis*) and wood mouse (*Apodemus sylvaticus*) from different types of polluted environment in Slovakia. *Environmental Monitoring Assessment*, vol. 171, no. 1-4, p. 651-660. <http://dx.doi.org/10.1007/s10661-010-1310-1> PMID: 20135219
- Martiniaková, M., Chovancová, H., Boboňová, I., Omelka, R. 2013a. *Účinky rizikových látok na štruktúru kostného tkaniva potkanov*. Nitra: Fakulta prírodných vied UKF, p. 187. ISBN 978-80-558-0295-4.
- Martiniaková, M., Boboňová, I., Omelka, R., Grosskopf, B., Chovancová, H., Španková, J., Toman, R. 2013b. Simultaneous subchronic exposure to selenium and diazinon as possible risk factor for osteoporosis in adult male rats. *Acta Veterinaria Scandinavica*, vol. 55, p. 8. <http://dx.doi.org/10.1186/1751-0147-55-81> PMID: 24237628
- Mody, N., Parhami, F., Sarafian, T. A., Demer, L. L. 2001. Oxidative stress modulates osteoblastic differentiation of vascular and bone cells. *Free Radical Biology and Medicine*, vol. 31, no. 4, p. 509-519. [http://dx.doi.org/10.1016/S0891-5849\(01\)00610-4](http://dx.doi.org/10.1016/S0891-5849(01)00610-4) PMID: 11498284
- Orimo, H., Ouchi, Y. 1990. The role of calcium and magnesium in the development of atherosclerosis. Experimental and clinical evidence. *Annals of the New York Academy of Sciences*, vol. 598, p. 444-457. <http://dx.doi.org/10.1111/j.1749-6632.1990.tb42315.x> PMID: 2248457
- Patntirapong, S., Hauschka, P. V. 2007. Molecular Regulation of Bone Resorption by Hypoxia. *Orthopaedic Journal, Harvard Medical School*, p. 72-75.
- Ponticelli, C., Glasscock, R. J. 2009. In: *Treatment of Primary Glomerulonephritis*. New York: Oxford University Press, p. 481. ISBN 978-0-19-955288-7. <http://dx.doi.org/10.1093/med/9780199552887.001.0001>
- Ricqlès, A. J., Meunier, F. J., Castanet, J., Francillon-Vieillot, H. 1991. *Comparative microstructure of bone. Bone 3, Bone Matrix and Bone Specific Products*. Hall BK. Boca Raton: CRC Press; p. 1-78. ISBN 0-8493-8823-6.
- Saruta, T. 1996. Mechanism of Glucocorticoid-Induced Hypertension. *Hypertension Research*, vol. 19, no. 1, p. 1-8. <http://dx.doi.org/10.1291/hyres.19.1> PMID: 8829818
- Shou, Y., Gunasekar, P. G., Borowitz, J. L., Isom, G. E. 2000. Cyanide-induced apoptosis involves oxidative-stress-activated NF-kappaB in cortical neurons. *Toxicology and Applied Pharmacology*, vol. 164, no. 2, p. 196-205.

<http://dx.doi.org/10.1006/taap.2000.8900>

[PMid: 10764633](#)

Song, Z., Xu, X. 2014. Advanced research on anti-tumor effects of amygdalin. *Journal of Cancer Research and Therapeutics*, vol. 10, suppl. no. 1, p. 3-7.

<http://dx.doi.org/10.4103/0973-1482.139743>

[PMid: 25207888](#)

Speijers, G. 1993. Cyanogenic glycosides. WHO Food Additives Series 30. Geneva. JECFA.

Szulc, P., Seeman, E., Duboeuf, F., Sornay-Rendu, E., Delmas, P. D. 2006. Bone fragility: failure of periosteal apposition to compensate for increased endocortical resorption in postmenopausal women. *Journal of Bone and Mineral Research*, vol. 21, no. 12, p. 1856-1863.

<http://dx.doi.org/10.1359/jbmr.060904>

Tewe, O. O., Maner, J. H. 1980. Cyanide, protein and iodine interactions in the performance, metabolism and pathology of pigs. *Research in Veterinary Science*, vol. 29, no. 3, p. 271-276. [PMid: 7255888](#)

Ullian, M. E. 1999. The role of corticosteroids in the regulation of vascular tone. *Cardiovascular Research*, vol. 41, no. 1, p. 55-64. [http://dx.doi.org/10.1016/S0008-6363\(98\)00230-2](http://dx.doi.org/10.1016/S0008-6363(98)00230-2)

Vetter, J. 2000. Plant cyanogenic glycosides. *Toxicon*, vol. 38, no. 1, p. 11-36. [http://dx.doi.org/10.1016/S0041-0101\(99\)00128-2](http://dx.doi.org/10.1016/S0041-0101(99)00128-2)

[PMid: 10669009](#)

Wang, Y., Zhao, L., Wang, Y., Xu, J., Nie, Y., Guo, Y., Tong, Y., Qin, L., Zhang, Q. 2012. Curculigoside isolated from *Curculigo orchoides* prevents hydrogen peroxide-induced dysfunction and oxidative damage in calvarial osteoblasts. *Acta Biochimica et Biophysica Sinica (Shanghai)*, vol. 44, no. 5, p. 431-441.

<http://dx.doi.org/10.1093/abbs/gms014>

[PMid: 22427460](#)

Waypa, G. B., Chandel, N. S., Schumacker, P. T. 2001. Model for Hypoxic Pulmonary Vasoconstriction Involving Mitochondrial Oxygen Sensing. *Circulation Research*, vol. 88, no. 12, p. 1259-1266.

<http://dx.doi.org/10.1161/hh1201.091960>

[PMid: 11420302](#)

Weir, E. K., Archer, S. L. 1995. The mechanism of acute hypoxic pulmonary vasoconstriction: the tale of two channels. *Federation of American Societies for Experimental Biology Journal*, vol. 9, no. 2, p. 183-189. [PMid: 7781921](#)

Yang, C., Li, X., Rong, J. 2014. Amygdalin isolated from *Semen Persicae (Tao Ren)* extracts induces the expression of follistatin in HepG2 and C2C12 cell lines. *Chinese Medicine*, vol. 9, p. 1-8. <http://dx.doi.org/10.1186/1749-8546-9-23>

[PMid: 25237385](#)

Yarema, T. C., Yost, S. 2011. Low-Dose Corticosteroids to Treat Septic Shock: A critical Literature Review. *Critical Care Nurse*, vol. 31, no. 6, p. 16-26.

<http://dx.doi.org/10.4037/ccn2011551>

[PMid: 22135328](#)

Yildirim, F. A., Askin, M. A. 2010. Variability of amygdalin content in seeds of sweet and bitter apricot cultivars in Turkey. *Africal Journal of Biotechnology*, vol. 9, no. 39, p. 6522-6524.

Zhou, C., Qian, L., Ma, H., Yu, X., Zhang, Y., Qu, W., Zhang, X., Xia, W. 2012. Enhancement of amygdalin activated with  $\beta$ -D-glucosidase on HepG2 cells proliferation and apoptosis. *Carbohydrate Polymers*, vol. 90, no. 1, p. 516-523.

<http://dx.doi.org/10.1016/j.carbpol.2012.05.073>

[PMid: 24751072](#)

#### **Acknowledgments:**

This study was supported by the grants VEGA 1/0653/16, KEGA 031UKF-4/2016 and Slovak Research and Development Agency APVV-0304-12.

#### **Contact address:**

Veronika Kováčová, Constantine the Philosopher University, Faculty of Natural Sciences, Department of Zoology and Anthropology, 949 74 Nitra, Slovakia, E-mail: veroni.kovacova@gmail.com.

Radoslav Omelka, Constantine the Philosopher University, Faculty of Natural Sciences, Department of Botany and Genetics, 949 74 Nitra, Slovakia, E-mail: romelka@ukf.sk.

Anna Šarocká, Constantine the Philosopher University, Faculty of Natural Sciences, Department of Zoology and Anthropology, 949 74 Nitra, Slovakia, E-mail: sarocka.anna@gmail.com.

Patrik Šranko, Constantine the Philosopher University, Faculty of Natural Sciences, Department of Botany and Genetics, 949 74 Nitra, Slovakia, E-mail: patriksranko@gmail.com.

Mária Adamkovičová, Constantine the Philosopher University, Faculty of Natural Sciences, Department of Botany and Genetics, 949 74 Nitra, Slovakia, E-mail: madamkovicova@ukf.sk.

Róbert Toman, Slovak University of Agriculture, Faculty of Agrobiological and Food Resources, Department of Veterinary Sciences, 949 76 Nitra, Slovakia, E-mail: robert.toman@uniag.sk.

Marek Halenár, Slovak University of Agriculture, Faculty of Biotechnology and Food Sciences, Department of Animal Physiology, 949 76 Nitra, Slovakia, E-mail: halenarmarek@gmail.com.

Adriana Kolesárová, Slovak University of Agriculture, Faculty of Biotechnology and Food Sciences, Department of Animal Physiology, 949 76 Nitra, Slovakia, E-mail: adriana.kolesarova@uniag.sk.

Monika Martiniaková, Constantine the Philosopher University, Faculty of Natural Sciences, Department of Zoology and Anthropology, 949 74 Nitra, Slovakia, E-mail: mmartiniakova@ukf.sk.