

THE EFFECT OF PATULIN ON FEMORAL BONE STRUCTURE IN MALE RABBITS

Veronika Kováčová, Hana Ďúranová, Ramona Babosová, Radoslav Omelka, Vladimíra Krajčovičová, Robert Stawarz, Marcela Capcarová, Monika Martiniaková

ABSTRACT

A lot of kinds of crops are susceptible to fungal attack, leading to considerable financial losses and damage the health of humans and animals. Patulin, a toxic fungal metabolite, can be found mainly in apple and apple products, with much less frequent contamination in other food products. Because of its high incidence and harmful health effects, patulin belongs to a class of mycotoxins, which are strictly monitored. However, its effect on bone structure is still unknown. This study was designed to investigate the impact of patulin on femoral bone structure in adult male rabbits. Four month-old male rabbits were randomly divided into two groups of three animals each. Rabbits from the experimental group (group A, n=3) were intramuscularly administered with patulin at dose 10 $\mu\text{g}\cdot\text{kg}^{-1}$ body weight (b.w.) twice a week for 4 weeks. The second group without patulin administration served as a control (group B, n=3). At the end of the experiment, body weight, femoral weight and length, cortical bone thickness and histological structure of femoral bones from all rabbits were determined. The results did not show any significant differences in body weight, femoral weight and length between experimental and control groups of rabbits. On the other hand, intramuscular application of patulin induced a significant increase in cortical bone thickness ($p < 0.05$) and considerable changes in qualitative histological characteristics of compact bone in adult male rabbits. In patulin-intoxicated males, the primary vascular longitudinal bone tissue was absent near endosteal border. On the other hand, this tissue occurred near *periosteum* and also in the middle part of the femoral bone in these rabbits. The values for the primary osteons' vascular canals were significantly lower ($p < 0.05$) in males exposed to patulin as compared to the control group. Based on these findings we can conclude that intramuscular patulin administration demonstrably influences cortical bone thickness and histological structure of femoral bone in adult male rabbits.

Keywords: patulin; femoral bone; rabbit; histomorphometry

INTRODUCTION

Many species of fungi may produce secondary metabolites, known as mycotoxins (Jay, 2000; Hosseini and Bagheri, 2012; Alexa et al., 2013). Mycotoxins exert toxic effects on animals and humans (Peraica et al., 1999). They may cause mycotoxicosis, which can result in an acute or chronic disease episode (Bryden, 2007).

Mycotoxin patulin, 4-hydroxy-4H-furo[3,2c]pyran-2(6H)-one, is produced by a number of fungi species (Bennett and Klich, 2003; Moake et al., 2005), such as *Penicillium* (mainly *Penicillium expansum*), *Aspergillus*, *Byssosclamyces* and *Paecilomyces* (Gimeno and Martins, 2006; Ionescu et al., 2010; Puel et al., 2010), which are likely natural contaminants of various food (Becci et al., 1981). Patulin has been found as a contaminant in many mouldy fruits, vegetables, cereals (Beltrán et al., 2014). According to Piqué et al. (2013), it is mainly presented in apples and apple-based products.

Although patulin had originally been considered as an antibiotic, it has adverse impacts on human health (Bennett and Klich, 2003). Several studies have found that patulin is genotoxic (Hopmans, 1997), cytotoxic (Glaser and Stopper, 2012), neurotoxic, mutagenic

(Beltrán et al., 2014), immunotoxic (Fernández-Cruz et al., 2010), teratogenic (Özsoy et al. 2008), carcinogenic (González-Osnaya et al., 2007) and embryotoxic (Piqué et al., 2013) agent.

In the study by Selmanoğlu (2006), some histopathological alternations were observed in the epididymis and prostate tissues in rats orally treated with patulin for 90 days. Also, patulin-induced degeneration and necrosis in liver tissues, as well as degeneration of glomeruli and haemorrhage between the tubules of the cortical region in kidney tissues were reported in male rats (Al-Hazmi, 2012). However, the effect of patulin on bone microstructure had not been studied prior to our experiment.

The aim of the present study was to determine the effect of patulin on selected growth characteristics (body weight, femoral weight, femoral length and cortical bone thickness) and femoral bone microstructure in male rabbits.

MATERIAL AND METHODOLOGY

Adult male rabbits (n=6) of meat line M91 (Californian broiler line) were used in the experiment. Animals (at the

age of 4 months, weighing 3.5 – 4.0 kg) were obtained from an experimental farm of the Animal Production Research Centre in Nitra, Slovak Republic. Male rabbits were used because they are less susceptible to skeletal damage than females (Riggs et al., 2004). Males were housed in individual flat-deck wire cages (area 0.3 m²) under standard conditions (temperature 20 – 22 °C, humidity 55 ±10 %, 12/12 h cycle of light and darkness) with access to food (feed mixture) and drinking water *ad libitum*.

Clinically healthy animals were randomly divided into two groups of three individuals each. In the first group (A), adult rabbits were intramuscularly injected with patulin (10 µg.kg⁻¹ b.w.) two times per week for four weeks. The dose of patulin was estimated based on literature data (FAO, 2004). The second group (B; n=3) without patulin intoxication served as a control. The Animal Experimental Committee of the Slovak Republic approved all procedures.

At the end of the experiments, all the rabbits were euthanized, weighed and their femurs were collected for macroscopical and microscopical analyses. The femurs were weighed on analytical scales with an accuracy of 0.01 g and the femoral length was measured with a caliper. For histological analysis, the right femurs were sectioned at the midshaft of the diaphysis and the segments were fixed in HistoChoice fixative (Amresco, USA). The segments were then dehydrated with a graded series (40 to 100 %) of ethanol and embedded in Biodur epoxy resin (Günter von Hagens, Heidelberg, Germany) according to the method described by Martiniaková et al. (2008). Transverse thin sections (70–80 µm) were prepared with a sawing microtome (Leitz 1600, Leica, Wetzlar, Germany) and fixed onto glass slides by Eukitt (Merck, Darmstadt, Germany) as previously described (Martiniaková et al., 2010). The qualitative histological characteristics of the compact bone tissue were determined according to the internationally accepted classification systems of Enlow and Brown (1956) and Ricqlés et al. (1991). The quantitative (histomorphometrical) variables were assessed using the software Motic Images Plus 2.0 ML (Motic China Group Co., Ltd.). We measured area, perimeter and

the minimum and maximum diameters of primary osteons' vascular canals, Haversian canals and secondary osteons in all views (i.e., anterior, posterior, medial and lateral) of the thin sections in order to minimize inter-animal differences. Diaphyseal cortical bone thickness was also measured by Motic Images Plus 2.0 ML software. Twenty random areas were selected and average thickness was calculated for each femur.

Statistical analysis was performed using SPSS 8.0 software (SPSS Inc., USA). All data were expressed as mean ± standard deviation (SD). The unpaired Student's T-test was used for establishing statistical significance ($p < 0.05$) between groups A and B.

RESULTS

Our results showed non-significant impact of patulin intramuscular administration on body weight, femoral weight and femoral length in male rabbits. On the other hand, cortical bone thickness was considerably increased ($p < 0.05$) in these animals (Table 1).

Femoral diaphysis of rabbits from the group B had a common bone microstructure. The periosteal and endosteal surfaces were formed mainly by primary vascular longitudinal bone tissue, as a basic structural pattern of all bones. The tissue was created by vascular canals, which ran in a direction essentially parallel to the long axis of the bone. Additionally, primary vascular radial bone tissue (created by branching or non-branching vascular canals radiating from the marrow cavity) was also identified in some areas near the endosteal surface. The middle part of *substantia compacta* was formed by dense Haversian (characterized by a large number of secondary osteons) or irregular Haversian (characterized by an occurrence of scattered secondary osteons) bone tissues (Figure 1).

In rabbits exposed to patulin, an absence of the primary vascular longitudinal bone tissue near the endosteal surface was found. This part of bone was created only by dense Haversian bone tissue. The periosteal surface was composed of primary vascular longitudinal bone tissue, which also occurred in some areas of the middle part of the compact bone (Figure 2).




Fig. 1 Microscopical structure of compact bone in rabbits from the group B: 1 – primary vascular longitudinal bone tissue, 2 – dense Haversian bone tissue, 3 – primary vascular radial bone tissue.

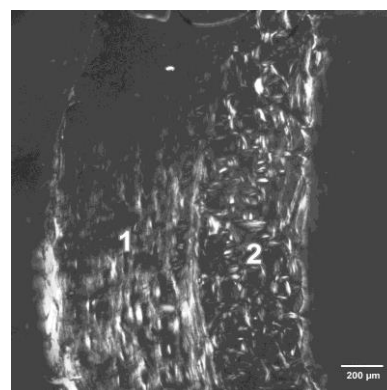


Fig. 2 Microscopical structure of compact bone in rabbits from the group A: 1 – primary vascular longitudinal bone tissue, 2 – dense Haversian bone tissue.

Table 1 Body weight, femoral weight, femoral length and cortical bone thickness in rabbits injected with patulin (10 µg.kg⁻¹ b.w.; group A) and the control rabbits (group B).

Rabbit's group	N	Body weight (g)	Femoral weight (g)	Femoral length (cm)	Cortical bone thickness (mm)
B	3	4152.9 ±212.2	14.53 ±1.39	10.51 ±0.25	997.51 ±92.95
A	3	4324.3 ±326.9	14.33 ±1.12	10.54 ±0.29	1059.31 ±118.93
T-test		NS	NS	NS	P < 0.05

N: number of rabbits, NS: non-significant changes

Table 2 Data on primary osteons' vascular canals in rabbits from A and B groups.

Rabbit's group	N	Area (µm ²)	Perimeter (µm)	Max. diameter (µm)	Min. diameter (µm)
B	124	320.76 ±48.60	64.23 ±4.87	11.13 ±1.09	9.22 ±1.02
A	125	262.05 ±58.01	58.01 ±6.32	10.03 ±1.43	8.34 ±1.12
T-test		p < 0.05	p < 0.05	p < 0.05	p < 0.05

N: number of measured structures; NS: non-significant changes

Table 3 Data on Haversian canals in rabbits from A and B groups.

Rabbit's group	N	Area (µm ²)	Perimeter (µm)	Max. diameter (µm)	Min. diameter (µm)
B	85	388.51 ±117.66	70.22 ±10.84	12.14 ±2.16	10.07 ±1.69
A	90	398.57 ±130.97	70.87 ±11.58	12.23 ±2.18	10.21 ±1.82
T-test		NS	NS	NS	NS

N: number of measured structures; NS: non-significant changes

Table 4 Data on secondary osteons in rabbits from A and B groups.

Rabbit's group	N	Area (µm ²)	Perimeter (µm)	Max. diameter (µm)	Min. diameter (µm)
B	85	8846.06 ±3950.00	332.25 ±84.17	58.98 ±16.79	45.46 ±11.05
A	90	9627.27 ±4356.66	345.41 ±77.95	60.44 ±14.31	48.54 ±11.71
T-test		NS	NS	NS	NS

N: number of measured structures; NS: non-significant changes

For the quantitative histological analysis, 249 vascular canals of the primary osteons, 175 Haversian canals and 175 secondary osteons were measured in total. The results are summarized in Tables 2, 3 and 4. We have found that all measured variables (area, perimeter, maximum and minimum diameters) of the Haversian canals and secondary osteons did not differ between rabbits from both investigated groups. On the other hand, the size of the primary osteons' vascular canals significantly decreased ($p < 0.05$) in males from the group A.

DISCUSSION

The results of our study have shown that intramuscular application of patulin had not significant effect on total body weight, femoral weight and length in adult male rabbits. Similarly, no demonstrable alterations in the body

weight gain were also reported in rats intoxicated with patulin at a dose of 0.1 mg.kg⁻¹ b.w./day in drinking water for 60 or 90 days (Selmanoğlu and Koçkaya, 2004; Selmanoğlu, 2006). Additionally, body weight and weight of various organs (e.g., liver, spleen, thymus, kidney with adrenals and lungs) were unchanged in female mice orally exposed to patulin (at the doses of 0.08, 0.16, 0.32, 0.64, 1.28 and 2.56 mg.kg⁻¹ b.w.) for 28 days (Llewellyn et al., 1998).

Skeletal growth is the result of complex interplay of nutritional, genetic and hormonal factors. Regarding the hormones, essential roles in normal skeletal development play thyroid and growth hormones. It is known that growth hormone deficiency produces severe generalized failure of osteogenesis (Braverman et al., 2005; Lieberman and Friedlaender, 2005) and decreased triiodothyronine and

thyroxine levels may reduce the basal metabolic rate, which could be associated with growth retardation (Selmanoglu and Koçkaya, 2004). The results published by above mentioned authors (Selmanoglu and Koçkaya, 2004) revealed non-significant changes in the levels of thyroid stimulating hormone and growth hormone in growing rats after application of patulin at a dose of 0.1 mg.kg⁻¹ b.w./day for a period of 60 or 90 days. This finding could signalize that patulin administration would not have an adverse impact on body weight and weight and length of femoral bone in these animals what is in accordance with our study.

Higher values for cortical bone thickness in male rabbits with patulin intoxication can be attributed to intensive formation of bone tissue within periosteal surface as an adaptive response to bone tissue against patulin toxicity. Under physiological conditions, width of bone increases with ageing due to periosteal apposition (Seeman, 2003). Periosteal bone formation can be stimulated by several agents, such as some hormones (Burr and Guillot, 2012). Parathormone is known to prevent apoptosis of periosteal osteoblasts (Jilka et al., 1999; Burr and Guillot, 2012), which could partly account for its effect on the cells in the osteogenic layer of the periosteum (Rhee et al., 2011; Burr and Guillot, 2012). The benefits of intermittent treatment with parathormone have been shown in experimental animals (Sato et al., 2002; Szulc et al., 2006). Osteoporotic postmenopausal women treated with human parathyroid hormone (1-34) had higher cortical thickness of iliac crest and higher width of distal radius (Dempster et al., 2001; Szulc et al., 2006). Sergeev et al. (1988) studied effects of aflatoxin B1 and T-2 toxin on metabolism of calcium and vitamin D. The young rats were administered daily within 7 days with these mycotoxins at the dose of 0.7 mg.kg⁻¹ and 0.54 mg.kg⁻¹ b.w. Administration of the mycotoxins caused hypocalcemia, decreased the concentration of 25(OH)D3 in blood serum and also lower activity of 25-hydroxylase D3 in liver tissue. In kidney, the activity of 24-hydroxylase tended to decrease. Likewise, the study by Glahn et al. (1991) demonstrated a decreased plasma 25-hydroxy vitamin D and 1,25-hydroxy vitamin D levels in three-week-old male broiler chickens after five days of aflatoxin treatment. In addition, total plasma calcium tended to be lower. These effects are connected with altered vitamin D and parathyroid hormone metabolism (Devegowda and Ravikiran, 2008). According to Lips (2001), deficiency in vitamin D causes secondary hyperparathyroidism, which leads to increased parathormone production. On the basis of these aspects we suppose that other mycotoxins (including patulin) should also have a similar effect on the concentrations of vitamin D and parathormone, which can be connected with evident changes in cortical bone thickness.

According to Cilotti and Falchetti (2009) androgens may prevent the loss of cancellous bone and also stimulate periosteal cortical bone apposition, resulting in a larger bone size and thicker cortical bone in males (Kung, 2003). Generally, androgen receptors are found in all bone cells, i.e., osteoblasts, osteocytes and osteoclasts (Notelovitz, 2002). The most important androgen is a testosterone (Selmanoglu and Koçkaya, 2004; Callewaert et al.,

2010). It was found that testosterone increases periosteal and endosteal apposition, bone size, trabecular (Tuck and Francis, 2009) and cortical bone thickness (Gorton et al., 2005) in adolescent males. On the other hand, a reduction in testosterone decreases the rate of periosteal bone apposition (Kung, 2003). Significant increased serum testosterone levels after patulin administration (at a dose of 0.1 mg/kg b.w./day) for a period of 60 or 90 days were documented in the study by Selmanoglu and Kockaya (2004). On the basis of these aspects we propose that enlargement of bone tissue on periosteal bone surface could also be associated with patulin-modified increased testosterone concentration.

The results of qualitative histological analysis correspond with those reported by other authors (Enlow and Brown, 1956; Martiniaková et al., 2003; Chrenek et al., 2006). The basic structural pattern of compact bone was primary vascular longitudinal in both groups of rabbits. Also, primary vascular radial and dense Haversian or irregular Haversian bone tissues were identified. In males intoxicated with patulin, an absence of the primary vascular longitudinal bone tissue near endosteal surface can be connected with intensive endosteal resorption due to patulin toxicity. On the other hand, primary vascular longitudinal bone tissue was (in some areas) present not only near the periosteal surface but also in the middle part of the compact bone. This findings point to the enhanced periosteal apposition as a compensative mechanism of bone tissue against patulin-induced bone loss from endosteal surface. Studies with liver cells or liver slices have demonstrated that patulin treatment results in glutathione depletion, which is connected with oxidative stress. Patulin-modified increased intracellular oxidative stress was reported in human embryonic kidney and human promyelocytic leukemia cells (Liu et al., 2007). Bone resorption is the unique function of the osteoclasts (Teitelbaum, 2000). Osteoclasts have shown to be activated by reactive oxygen species (ROS) to enhance bone resorption (Baek et al., 2010). Therefore, we suppose that the absence of primary vascular longitudinal tissue near the endosteal surface can be attributed to oxidative stress-induced intensive bone resorption due to patulin toxicity.

The histomorphometrical measurements showed a significant constriction of the primary osteons' vascular canals in rabbits exposed to patulin. This fact can be related to adverse effect of patulin on blood vessels, which are present in vascular canals of primary osteons (Greenlee and Dunnell, 2010). The results of Broom et al. (1944) revealed a very small, transient vasoconstriction in rabbits after patulin administration at the dose of 0.08 mg.kg⁻¹ b.w. Recent experimental studies have demonstrated the direct action of androgens on the blood vessels. Long-term administration of testosterone may elicit harmful effects, especially vasoconstriction (Akishita and Yu, 2012). Furthermore, patulin has a strong affinity for sulfhydryl groups inhibiting the activity of many enzymes (Selmanoglu and Koçkaya, 2004; Puel et al., 2010; Zbynovská et al., 2013). Magan et al. (2004) found that patulin (at the dose of 1.6 mg.kg⁻¹ b.w.) inhibited acetylcholinesterase and NaK-ATPase in the cerebral hemisphere, cerebellum and *medulla oblongata* in

rats leading to higher levels of acetylcholine in these brain segments. Martiniaková et al. (2013) noted that increased levels of acetylcholine in the endothelium of blood vessels subsequently activated muscarinic receptors in the endothelium of vascular and Haversian canals in rats. According to Yoopan et al. (2008), the alteration of muscarinic function in blood vessel may contribute to hypertension. The binding of patulin to sulfhydryl groups of acetylcholinesterase might also explain this negative impact of this mycotoxin on the size of the primary osteons' vascular canals in rabbits from the group A.

CONCLUSION

Generally, exceeded recommended level of patulin in fruit juices and other fruit products may cause potential risk in humans, particularly in children.

The current study revealed a significant effect of intramuscular application of patulin at the dose of 10 µg.kg⁻¹ b.w. twice per week for 4 weeks on cortical bone thickness and the size of primary osteons' vascular canals in adult male rabbits. In addition, patulin application induced evident changes in femoral bone microstructure of these animals.

Anyway, our results indicate considerable impact of patulin on macroscopical and microscopical structures of femoral compact bone in adult male rabbits.

REFERENCES

- Akishita, M., Yu, J. 2012. Hormonal effects on blood vessels. *Hypertens Res.*, vol. 35, no. 4, p. 363-369. [PMid: 22297478](https://doi.org/10.1007/s12012-012-0147-8)
- Al-Hazmi, M. A. 2012. Patulin in apple juice and its risk assessments on albino mice. *Toxicol Ind Health*, vol. 25, no. 30, p. 534-545. [http://dx.doi.org/10.1177/0748233712457454](https://doi.org/10.1177/0748233712457454) [PMid:23012343](https://pubmed.ncbi.nlm.nih.gov/23012343/)
- Alexa, E., Dehelean, C. A., Poiana, M. A., Radulov, I., Cimpean, A. M., Bordean, D. M., Tulcan, C., Pop, G. 2013. The occurrence of mycotoxins in wheat from western Romania and histopathological impact as effect of feed intake. *Chemistry Central Journal*, vol. 7, p. 1-11. [http://dx.doi.org/10.1186/1752-153X-7-99](https://doi.org/10.1186/1752-153X-7-99) [PMid:23759114](https://pubmed.ncbi.nlm.nih.gov/23759114/)
- Baek, K. H., Oh, K. W., Lee, W. Y., Lee, S. S., Kim, M. K., Kwon, H. S., Rhee, E. J., Han, J. H., Song, K. H., Cha, B. Y., Lee, K. W., Kang, M. I. 2010. Association of oxidative stress with postmenopausal osteoporosis and the effects of hydrogen peroxide on osteoclast formation in human bone marrow cell cultures. *Calcif Tissue Int.*, vol. 87, p. 226-235. [http://dx.doi.org/10.1007/s00223-010-9393-9](https://doi.org/10.1007/s00223-010-9393-9) [PMid: 20614110](https://pubmed.ncbi.nlm.nih.gov/20614110/)
- Becci, P. J., Hess, F. G., Johnson, W. D., Gallo, M. A., Babish, J. G., Dailey, R. E., Parent, R. A. 1981. Long-term carcinogenicity and toxicity studies of patulin in the rat. *J. Appl. Toxicol.*, vol. 1, no. 5, p. 256-261. [PMid: 6821081](https://pubmed.ncbi.nlm.nih.gov/6821081/)
- Beltrán, E., Ibáñez, M., Sancho, J. V., Hernández, F. 2014. Determination of patulin in apple and derived products by UHPLC-MS/MS. Study of matrix effects with atmospheric pressure ionisation sources. *Food Chem.*, vol. 142, p. 400-407. [http://dx.doi.org/10.1016/j.foodchem.2013.07.069](https://doi.org/10.1016/j.foodchem.2013.07.069) [PMid: 24001858](https://pubmed.ncbi.nlm.nih.gov/24001858/)
- Bennett, J. W., Klich, M. 2003. Mycotoxins. *Clin. Microbiol. Rev.*, vol. 16, no. 3, p. 497-516. [http://dx.doi.org/10.1128/CMR.16.3.497-516.2003](https://doi.org/10.1128/CMR.16.3.497-516.2003) [PMC: 164220](https://pubmed.ncbi.nlm.nih.gov/164220/)
- Braverman, L. E., Werner, S. C., Ingbar, S. H., Utiger, R. D. 2005. *Werner & Ingbar's the Thyroid: A Fundamental and Clinical Text*. USA: Lippincott Williams & Wilkins, 1100 p., ISBN 0-7817-5047-4.
- Broom, W. A., Bülbiring, E., Chapman, C. J., Hampton, J. W. F., Thomson, A. M., Ungar, J., Wien, R., Woolfe, G. 1944. The Pharmacology of patulin. *Br. J. Exp. Pathol.*, vol. 25, no. 6, p. 195-207. [PMC: 2065635](https://pubmed.ncbi.nlm.nih.gov/2065635/)
- Bryden, W. L. 2007. Mycotoxins in the food chain: human health implications. *Asia Pac. J. Clin. Nutr.*, vol. 16, p. 95-101. [PMid: 17392084](https://pubmed.ncbi.nlm.nih.gov/17392084/)
- Burr, D. B., Guillot, G. M. 2012. Almost invisible, often ignored: periosteum, the living place of bone. *Medicographia*, vol. 34, p. 221-227. [cit. 2014-02-13] Available at: <http://www.medicographia.com/2012/11/almost-invisible-often-ignored-periosteum-the-living-lace-of-bone/>
- Callewaert, F., Boonen, S., Vanderschueren, D. 2010. Sex steroids and the male skeleton: a tale of two hormones. *Trends Endocrinol. Metab.*, vol. 21, no. 2, p. 89-95. [http://dx.doi.org/10.1016/j.tem.2009.09.002](https://doi.org/10.1016/j.tem.2009.09.002) [PMid: 19837603](https://pubmed.ncbi.nlm.nih.gov/19837603/)
- Cilotti, A., Falchetti, A. 2009. Male osteoporosis and androgenic therapy: from testosterone to SARMs. *Clin Cases Miner Bone Metab.*, vol. 6, no. 3, p. 229-233. [PMC: 2811355](https://pubmed.ncbi.nlm.nih.gov/2811355/)
- Dempster, D. W., Cosman, F., Kurland, E. S., Zhou, H., Nieves, J., Woelfert, L., Shane, E., Plavetić, K., Müller, R., Bilezikian, J., Lindsay, R. 2001. Effects of daily treatment with parathyroid hormone on bone microarchitecture and turnover in patients with osteoporosis: a paired biopsy study. *J. Bone Miner. Res.*, vol. 16, no. 10, p. 1846-1853. [http://dx.doi.org/10.1359/jbmr.2001.16.10.1846](https://doi.org/10.1359/jbmr.2001.16.10.1846) [PMid: 11585349](https://pubmed.ncbi.nlm.nih.gov/11585349/)
- Devegowda, G., Ravikiran, D. 2008. Mycotoxins and eggshell quality: cracking the problem. *World Mycotoxin J*, vol. 1, no. 2, p. 203-208. [http://dx.doi.org/10.3920/WMJ2008.1037](https://doi.org/10.3920/WMJ2008.1037)
- Enlow, D. H., Brown, S. O. 1956. A comparative histological study of fossil and recent bone tissues. Part I. *Tex. J. Sci.*, vol. 8, p. 405-412.
- Fernández-Cruz, M. L., Mansilla, M. L., Tadeo, J. L. 2010. Mycotoxins in fruits and their processed products: Analysis, occurrence and health implications. *J. Adv. Res.*, vol. 1, no. 2, p. 113-122. [http://dx.doi.org/10.1016/j.jare.2010.03.002](https://doi.org/10.1016/j.jare.2010.03.002)
- Food and Agriculture Organization (FAO): Worldwide Regulation for Mycotoxins in Food and Feed in 2003. FAO Food and Nutrition Papers 81. Rome: FAO; 2004.
- Gimeno, A., Martins, M. L. 2006. *Mycotoxins and Mycotoxicosis in Animals and Humans*. USA: Special Nutrients, Inc., 127 p.
- Glahn, R. P., Beers, K. W., Bottje, W. G., Wideman R. F. Jr., Huff, W. E., Thomas, W. 1991. Aflatoxicosis alters avian renal function, calcium, and vitamin D metabolism. *J. Toxicol. Environ. Health.*, vol. 34, no. 3, p. 309-321. [PMid: 1942121](https://pubmed.ncbi.nlm.nih.gov/1942121/)
- Glaser, N., Stopper, H. 2012. Patulin: Mechanism of genotoxicity. *Food Chem. Toxicol.*, vol. 50, no. 5, p. 1796-1801. [http://dx.doi.org/10.1016/j.fct.2012.02.096](https://doi.org/10.1016/j.fct.2012.02.096) [PMid: 22425938](https://pubmed.ncbi.nlm.nih.gov/22425938/)
- González-Osnaya, L., Soriano, J. M., Moltó, J. C., Mañez, J. 2007. Exposure assessment to patulin from the consumption of apple-based products. *Food Addit. Contam.*, vol. 24, no. 11, p. 1-21. [http://dx.doi.org/10.1080/02652030701361556](https://doi.org/10.1080/02652030701361556)
- Gorton, R. N., Buth, J., Spade, D. 2005. *Medical Therapy and Health Maintenance for Transgender Men: A Guide For Health Care Providers*. San Francisco, CA: Lyon-Martin Women's Health Services. p. 98, ISBN 0-9773250-0-8.

- Greenlee, D. M., Dunnell, R. C. 2010. Identification of fragmentary bone from the Pacific. *J. Archaeol. Sci.*, vol. 37, no. 5, p. 957-970. <http://dx.doi.org/10.1016/j.jas.2009.11.029>
- Hopmans, E. C. 1997. Patulin: a mycotoxin in apples. *Perishables Handling Quarterly*, no. 91, p. 5-6.
- Hosseini, S. S., Bagheri, R. 2012. Some major mycotoxin and their mycotoxicoses in nuts and dried fruits. *Intl. J. Agron. Plant. Prod.*, vol. 3, no. 5, p. 179-184. [cit. 2014-02-7] Available at: <http://ijappjournal.com/wp-content/uploads/2012/179-184.pdf>
- Chrenek, P., Bátorová, A., Bauer, M., Bauerová, M., Bulla, J., Dragin, S., Fabiš, M., Foltýs, V., Gažovičová, Z., Grosskopf, B., Hanusová, E., Hetényi, L., Chrastinová, L., Jurčík, R., Kačmárik, J., Kirchnerová, K., Kubovičová, E., Kuklová, Ž., Lukáč, N., Makarevič, A., Martiniaková, M., Massányi, P., Novotná, K., Omelka, R., Paleyanda, R., Parkányi, V., Peškovičová, D., Pivko, J., Popelková, M., Rafay, J., Ryban, L., Sirotkin, A., Süvegová, K., Trandžik, J., Vondráková, M., Žilka, N. 2006. *Produkcia a analýza transgénnych králikov. (The production and analysis of transgenic rabbits)* 1st ed. Nitra: SCPV v Garmond, 237 p., ISBN 80-88872-54-5.
- Ionescu, V., Catana, M., Catana, L., Negoita, M., Iorga, E., Balea, A., Campeanu, G. 2010. Evaluation of patulin contamination of apple juice, using high performance liquid chromatography. *Chem Bull „POLITEHNICA“ Univ. (Timisoara)*, vol. 55, no. 69, p. 186-188. [cit. 2014-02-13] Available at: http://www.chemicalbulletin.ro/admin/articole/59159art_19_186-188_.pdf
- Jay, J. M. 2000. *Modern Food Microbiology - Sixth Edition*. USA: Aspen Publishers, Inc., p. 720 ISBN 0-8342-1671-X.
- Jilka, R. L., Weinstein, R. S., Bellido, T., Roberson, P., Parfitt, A. M., Manolagas, S. C. 1999. Increased bone formation by prevention of osteoblast apoptosis with parathyroid hormone. *J. Clin. Invest.*, vol. 104, no. 4, p. 439-446. <http://dx.doi.org/10.1172/JCI6610>
- Kung, A. W. C. 2003. Androgen and bone mass in men. *Asian J. Androl.*, vol. 5, p. 148-154. [PMid: 12778327](http://dx.doi.org/10.1172/JCI6610)
- Lieberman, J. R., Friedlaender, G. E. 2005. *Bone Regeneration and Repair: Biology and Clinical Applications*. USA: New Jersey: Humana Press Inc., 398 p. ISBN 0-89603-847-5.
- Lips, P. 2001. Vitamin D deficiency and secondary hyperparathyroidism in the elderly: consequences for bone loss and fractures and therapeutic implications. *Endocr. Rev.*, vol. 22, no. 4, p. 477-501. [PMid: 11493580](http://dx.doi.org/10.1172/JCI6610)
- Liu, B. H., Wu, T. S., Yu, F. Y., Su, C. C. 2007. Induction of oxidative stress response by the mycotoxin patulin in mammalian cells. *Toxicol. Sci.*, vol. 95, no. 2, p. 340-347. <http://dx.doi.org/10.1093/toxsci/kfl156> [PMid: 17090621](http://dx.doi.org/10.1016/S0278-6915(98)00084-2)
- Llewellyn, G. C., McCay, J. A., Brown, R. D., Musgrove, D. L., Butterworth, L. F., Munson, A. E., White, K. L. jr. 1998. Immunological evaluation of the mycotoxin patulin in female B6C3F1 mice. *Food Chem. Toxicol.*, vol. 36, no. 12, p. 1107-1015. [http://dx.doi.org/10.1016/S0278-6915\(98\)00084-2](http://dx.doi.org/10.1016/S0278-6915(98)00084-2) [PMid: 9862653](http://dx.doi.org/10.1016/S0278-6915(98)00084-2)
- Magan, N., Olsen, M., Kuiper-Goodman, T., Arcella, D., Leclercq, C., Van Egmond, H. P., Jonker, M. A., Whitaker, T. B., Patel, P., Nicholson, P., Aldred, D., Sanchis, V., Shapira, R., Scudamore, K. A., Battilani, P., Pietri, A., Pettersson, H., Aish, J. L., Rippon, E. H., Barlow, T., Hattersley, S. J. 2004. *Mycotoxins in Food: Detection and Control*. England: Woodhead Publishing Limited, 488 p. ISBN 0-8493-2557-9.
- Martiniaková, M., Vondráková, M., Fabiš, M. 2003. Investigation of the microscopic structure of rabbit compact bone tissue. *Scripta medica (Brno)*, vol. 76, no. 4, p. 215-220.
- Martiniaková, M., Omelka, R., Grosskopf, B., Sirotkin, A. V., Chrenek, P. 2008. Sex-related variation in compact bone microstructure of the femoral diaphysis in juvenile rabbits. *Acta Veterinaria Scandinavica*, vol. 50, p. 15. <http://dx.doi.org/10.1186/1751-0147-50-15> [PMid:18522730](http://dx.doi.org/10.1186/1751-0147-50-15)
- Martiniaková, M., Omelka, R., Jančová, A., Stawarz, R., Formicki, G. 2010. Heavy metal content in the femora of yellow-necked mouse (*Apodemus flavicollis*) and wood mouse (*Apodemus sylvaticus*) from different types of polluted environment in Slovakia. *Environ. Monit. Assess.*, vol. 171, no. 1-4, p. 651-660. <http://dx.doi.org/10.1007/s10661-010-1310-1> [PMid: 20135219](http://dx.doi.org/10.1007/s10661-010-1310-1)
- Martiniaková, M., Chovancová, H., Boboňová, I., Omelka, R. 2013. *Účinky rizikových látok na štruktúru kostného tkaniva potkanov. (The effects of risk substances on the bone tissue structure in rats)* Nitra: Faculty of Natural Sciences, UKF, 187 p. ISBN 978-80-558-0295-4.
- Moake, M. M., Padilla-Zakour, O. I., Worobo, R. W. 2005. Comprehensive Review of Patulin Control Methods in Foods. *Compr. Rev. Food Sci. F.*, vol. 1, p. 8-21. <http://dx.doi.org/10.1111/j.1541-4337.2005.tb00068.x>
- Özsoy, N., Selmanoğlu, G., Koçkaya, E. A., Gül, N., Cebesoy, S. 2008. Effect of patulin on the interdigitating dendritic cells (IDCs) of rat thymus. *Cell Biochem Funct*, vol. 26, no. 2, p. 192-196. <http://dx.doi.org/10.1002/cbf.1431> [PMid: 17702051](http://dx.doi.org/10.1002/cbf.1431)
- Notelovitz, M. 2002. Androgen effects on bone and muscle. *Fertil Steril.*, vol. 77, suppl. 4, p. 34-41. [http://dx.doi.org/10.1016/S0015-0282\(02\)02968-0](http://dx.doi.org/10.1016/S0015-0282(02)02968-0) [PMid: 12007900](http://dx.doi.org/10.1016/S0015-0282(02)02968-0)
- Peraica, M., Radić, B., Lucić, A., Pavlović, M. 1999. Toxic effects of mycotoxins in humans. *B World Health Organ*, vol. 77, p. 754-766. [PMC2557730](http://dx.doi.org/10.1186/14752875730)
- Piqué, E., Vargas-Murga, L., Gómez-Catalán, J., Llobet, J. M. 2013. *Occurrence of patulin in organic and conventional apple juice. Risk assessment*. Recent Advances in Pharmaceutical Sciences III, Transworld Research Network, p. 131-144 ISBN: 978-81-7895-605-3.
- Puel, O., Galtier, P., Oswald, I. P. 2010. Biosynthesis and toxicological effects of patulin. *Toxins (Basel)*, vol. 2, no. 4, p. 613-631. <http://dx.doi.org/10.3390/toxins2040613>
- Rhee, Y., Allen, M. R., Condon, K., Lezcano, V., Ronda, A. C., Galli, C., Olivos, N., Passeri, G., O'Brien, C. A., Bivi, N., Plotkin L. I., Bellido, T. 2011. PTH receptor signaling in osteocytes governs periosteal bone formation and intracortical remodeling. *J. Bone Miner. Res.*, vol. 26, no. 5, p. 1035-1046. <http://dx.doi.org/10.1002/jbmr.304> [PMid: 21140374](http://dx.doi.org/10.1002/jbmr.304)
- Ricqlès, A. J., Meunier, F. J., Castanet, J., Francillon-Vieillot, H. 1991. *Comparative microstructure of bone. Bone 3, Bone Matrix and Bone Specific Products*. Hall BK. Boca Raton: CRC Press; p. 1-78. ISBN 0-8493-8823-6.
- Riggs, B. L., Melton III, L. J., Robb, R. A., Camp, J. J., Atkinson, E. J., Peterson, J. M., Rouleau, P. A., McCollough, C. H., Boussein, M. L., Khosla, S. 2004. Population-based study of age and sex differences in bone volumetric density, size, geometry, and structure at different skeletal sites. *J. Bone Miner. Res.*, vol. 19, no. 12, p. 1945-1954. <http://dx.doi.org/10.1359/jbmr.040916> [PMid: 15537436](http://dx.doi.org/10.1359/jbmr.040916)
- Sato, M., Vahle, J., Schmidt, A., Westmore, M., Smith, S., Rowley, E., Ma, L. Y. 2002. Abnormal bone architecture and biomechanical properties with near-lifetime treatment of rats

with PTH. *Endocrinology*, vol. 143, no. 9, p. 3230-3242.

<http://dx.doi.org/10.1210/en.2002-220149> PMID: 12193534

Seeman, E. 2003. Periosteal bone formation - a neglected determinant of bone strength. *N. Engl. J. Med.*, vol. 349, no. 4, p. 320-323. <http://dx.doi.org/10.1056/NEJMp038101> PMID: 12878736

Selmanoğlu, G. 2006. Evaluation of the reproductive toxicity of patulin in growing male rats. *Food Chem. Toxicol.*, vol. 44, no. 12, p. 2019-2024. <http://dx.doi.org/10.1016/j.fct.2006.06.022> PMID: 16905234

Selmanoglu, G., Koçkaya, E. A. 2004. Investigation of the effects of patulin on thyroid and testis, and hormone levels in growing male rats. *Food Chem. Toxicol.*, vol. 42, no. 5, p. 721-727. PMID: 15046817

Sergeev, I. N., Arkhapchev I. u. P., Kravchenko, L. V., Kodentsova V. M., Piliia, N. M. 1988. Effect of mycotoxins aflatoxin B1 and T-2 toxin on the vitamin D3 metabolism and binding of its hormonal form 1,25-dihydroxyvitamin D3 in rats. *Vopr. Med. Khim.*, vol. 34, no. 4, p. 51-57. PMID: 2848363

Szulc, P., Seeman, E., Duboeuf, F., Sornay-Rendu, E., Delmas, P. D. 2006. Bone fragility: failure of periosteal apposition to compensate for increased endocortical resorption in postmenopausal women. *J. Bone Miner. Res.*, vol. 21, no. 12, p. 1856-1863. <http://dx.doi.org/10.1359/jbmr.060904> PMID: 17002580

Teitelbaum, S. L. 2000. Bone resorption by osteoclasts. *Science*, vol. 289, no. 5484, p. 1504-1508. <http://dx.doi.org/10.1126/science.289.5484.1504> PMID: 10968780

Tuck, S. P. Francis, R. M. 2009. Testosterone, bone and osteoporosis. In: Jones, T. H. *Advances in the Management of Testosterone Deficiency*. Switzerland: Reinhardt Druck, Basel, Karger, p. 210. ISBN 978-3-8055-8622-1.

Yoopan, N., Watcharasit, P., Wongsawatkul, O., Piyachaturawat, P., Satayavivad, J. 2008. Attenuation of eNOS expression in cadmium-induced hypertensive rats. *Toxicol Lett.*, vol. 176, no. 2, p. 157-161. <http://dx.doi.org/10.1016/j.toxlet.2007.11.002> PMID: 18155860

Zbynovská, K., Emrichová, J., Kalařová, A., Petruška, P., Ondruška, L., Jurčík, R., Chrástínová, L., Kováčik, A., Schneidgenová, M., Tusimová, E., Capcarová, M. 2013. Haematological changes in rabbit's blood after two weeks exposure of patulin. *RFFCH Gödöllő*, p. 1-5. [cit. 2014-02-19] Available at: <http://mkk.szie.hu/dep/aeet/webhely/probaCD/prezentaciok/pdf/Zbynovska.pdf>

Acknowledgment:

This study was supported by the grants KEGA 035 UKF-4/2013, UGA VII/21/2014. This article was written during realization of the project CEGEZ No. 26220120073 supported by the Operational Programme Research and Development funded from the European Regional Development Fund.

Contact address:

Veronika Kováčová, Constantine the Philosopher University (CPU), Faculty of Natural Sciences (FNS), Department of Zoology and Anthropology (DZA), 949 74 Nitra, Slovakia, E-mail: veroni.kovacova@gmail.com.

Hana Ďúranová, CPU, FNS, DZA, 949 74 Nitra, Slovakia, E-mail: hduranova@ukf.sk.

Ramona Babosová, CPU, FNS, DZA, 949 74 Nitra, Slovakia, E-mail: ramona.babosova@ukf.sk.

Radoslav Omelka, CPU, FNS, Department of Botany and Genetics (DBG), 949 74 Nitra, Slovakia, E-mail: romelka@ukf.sk.

Vladimíra Krajčovičová, CPU, FNS, DBG, 949 74 Nitra, Slovakia, E-mail: vkrajcovicova@ukf.sk.

Robert Stawarz, Krakow Pedagogical University, Institute of Biology, 31 054 Krakow, Poland, E-mail: robert.stawarz@gmail.com

Marcela Capcarová, Slovak University of Agriculture in Nitra, Department of Animal Physiology, 949 76 Nitra, Slovakia, E-mail: marcela.capcarova@uniag.sk.

Monika Martiniaková, CPU, FNS, DZA, 949 74 Nitra, Slovakia, E-mail: mmartiniakova@ukf.sk.